

CASE STUDY

- 89% WOUND REDUCTION IN 10 WEEKS
- 4 MONTH OLD WOUND
- 10 ACTIGRAFT APPLICATIONS

PATIENT:

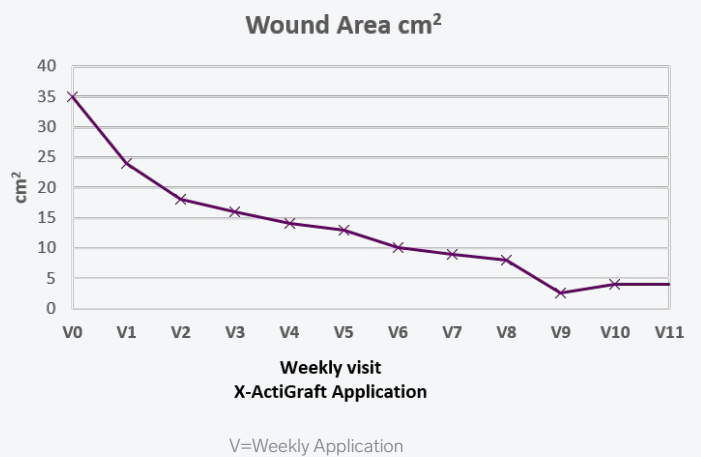
82 Year Old, Male

PAST MEDICAL HISTORY: Diabetes mellitus type 2, osteomyelitis, Ischemic heart disease, hypertension

WOUND HISTORY:

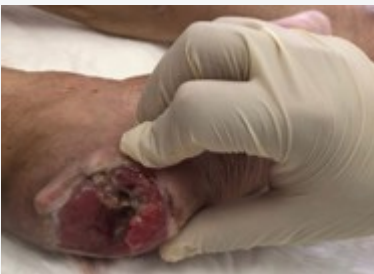- n/a

PAST TREATMENTS: Dermagran B, K-Sept



ACTIGRAFT TREATMENT PROGRESSION:

Week 1



Week 10

